



PATIENT

Jinx Connors

SPECIES

Feline

BREED

DLH

SEX

Female Spayed

AGE

4 years

WEIGHT

14.06lbs

INTERPRETED BY

Maggie Machen
Lamy, DVM
DACVIM (Cardiology)

IMAGING PERFORMED BY

Pamela Harrigan,
RDCS

HOSPITAL NAME

Mass Veterinary Services

REFERRING VET

Dr. Masloski

INVOICE

25536

DATE

7/26/22

PRESENTING CLINICAL SIGNS

History: Jinx is referred to evaluate a heart murmur noted in March. A ProBNP was normal. He is doing well with no clinical issues. Good appetite, active and playful. On exam: NSR, grade III/VI parasternal murmur, PSS, lung fields clear, compressible thorax. BP: 100 mmHg x 5. No medications. *No sedation for study

ECHOCARDIOGRAM FINDINGS

2D, m-mode, color flow and Doppler imaging is available.

Left ventricle: The LV diameter is mildly increased with adequate myocardial function. The LV wall thicknesses are irregular with regions of mild septal hypertrophy. There is a mildly hyperechoic endocardium consistent with mild fibrosis. The papillary muscles are mildly hypertrophied. The endocardium appears mildly remodeled.

Left atrium: The left atrium and auricle are mildly dilated. No spontaneous contrast or thrombi seen.

Mitral valve: The anterior leaflet of the mitral valve is mildly elongated. Abnormal anterior motion is seen during systole. Mild to moderate eccentric mitral regurgitation.

Aortic valve/Aorta: The aortic valve is normal in morphology and mobility. Mildly elevated LVOT outflow velocities with a dynamic profile. No aortic insufficiency.

Right ventricle: Normal right ventricular diameter and morphology indicating no overt evidence of pulmonary arterial hypertension.

Right atrium: The right atrium is normal in dimension.

Tricuspid valve: The tricuspid valve appears normal with no tricuspid regurgitation.

Pulmonary valve/Pulmonary artery: The pulmonic valve is normal in morphology and mobility. No pulmonic insufficiency. Normal RVOT velocity; laminar flow.

Pericardium/other: No pericardial or pleural effusion noted. No obvious cardiac masses.

Heart rhythm: ECG reveals a sinus rhythm with an average HR of 240bpm.

2-Dimensional Measurements

Ao diam (cm)	1.1
LA diam (cm)	1.5
LA:Ao (Swe)	1.4
IVS thickness (cm)	0.65
LVID diastole (cm)	2.0
PW thickness (cm)	0.44
LVID systole (cm)	0.9
FS (%)	55

Doppler Measurements

PV Vmax (m/s)	1.0
AoV Vmax (m/s)	2.7
MR Vmax (m/s)	NA
TR Vmax (m/s)	NA
TR PG (mmHg)	NA

INTERPRETATION OF THE FINDINGS

The likely diagnosis and cause of the murmur is mitral valve dysplasia leading to an obstructive LVOT flow pattern and mild/moderate MR. A primary hypertrophic component cannot be ruled out as a concurrent issue; however, with only mild LV changes this is unlikely. There is mild left atrial and auricular dilation, indicating the risk for imminent complication is low; however, there is concern for risk for progression to spontaneous CHF and/or a thrombotic event going forward. No additional issues are identified.

Long term prognosis is guarded given the age of the patient and highly variable nature of asymptomatic feline heart disease. Many cats will remain asymptomatic until mid-life or



PATIENT
Jinx Connors

beyond, while others develop CHF within the first years. Close monitoring for progression of LA dilation in the future will help determine long term prognosis.

SPECIES
Feline

While no medications have been shown to definitively alter long term outcome at this stage of disease, atenolol is often initiated to decrease the outflow obstruction. In cases of solely primary MV dysplasia this can lead to improvement in the degree of obstruction and hypertrophy. Given today's findings and marked tachycardia, consider institution at this time if possible. No additional medications are indicated prior to significant LA dilation.

BREED
DLH

RECOMMENDATIONS

- Administer titrating dose of atenolol: 25mg tablets; Give ¼ tab once daily. Recheck heart rate in 1-2 weeks with target stressed rate of 140-160bpm 12-24 hours post-administration. Increase as needed until target reached.
- Anesthetic risk is considered mildly elevated, however judicious IV fluid rates are advised to avoid fluid overload. Additionally, drugs that stimulate heart rate should be avoided unless clinically necessary (glycopyrrolate, atropine). Avoid vasodilators as this may worsen the obstruction. A reasonable protocol includes opioid/benzodiazepine premedication, propofol induction, isoflurane maintenance.
- Monitor for any clinical evidence of cardiac compromise, including respiratory changes and/or signs of a blood clot event (paralysis, neurologic changes, etc.).

SEX
Female Spayed

AGE
4 years

WEIGHT
14.06lbs

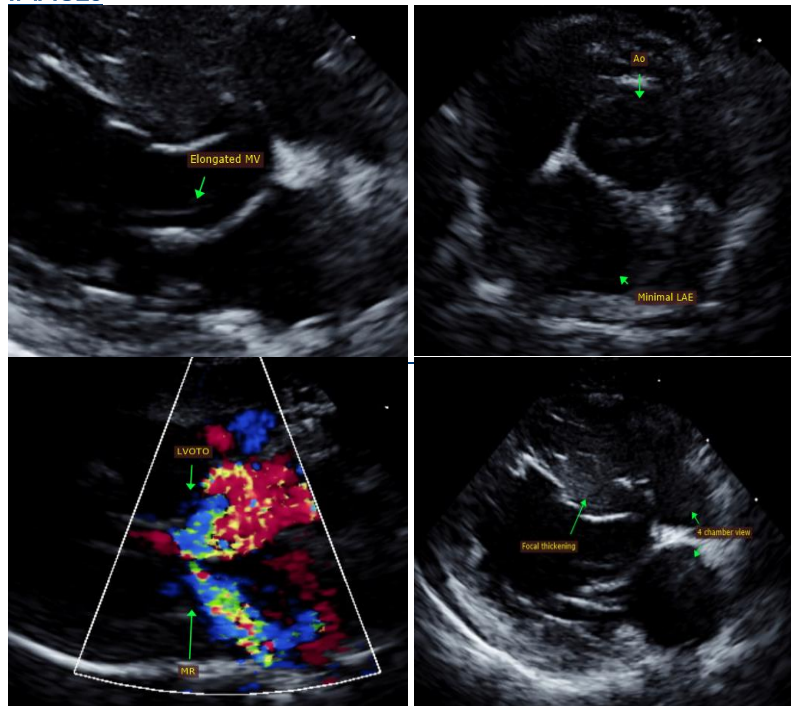
PLAN

- Recommend recheck echocardiogram in 6 months to assess for progression/regression, sooner if clinical signs arise in the interim.

INTERPRETED BY

Maggie Machen
Lamy, DVM
DACVIM (Cardiology)

IMAGES



IMAGING PERFORMED BY
Pamela Harrigan,
RDCS

HOSPITAL NAME
Mass Veterinary Services

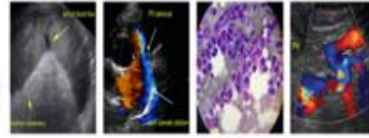
REFERRING VET
Dr. Masloski

INVOICE
25536

DATE
7/26/22



Mass Veterinary
Services



SonoPath
Clinical Sonography & Telectyology
EDUCATIONAL TELECONSULTATION SERVICES™
1-800-838-4268 info@sonopath.com SonoPath.com

PATIENT

Jinx Connors

The information and recommendations provided are based on the images presented by the referring veterinarian. No evaluation can be communicated regarding pathology that was not visible in the image/video clips provided.

SPECIES

Feline

Thank you for this referral. This report was generated using transcription software, and minor dictation errors may be present. If the clinical or image interpretation does not parallel your findings or if I can be of any further assistance, please contact me.

BREED

DLH

Maggie Machen Lamy, DVM
Diplomate of the American College of Veterinary Internal Medicine (Cardiology)
info@sonopath.com

SEX

Female Spayed

Echocardiogram performed by: Pamela Harrigan, RDCS
Pet Animal Ultrasound Service (4paus.com)

AGE

4 years

WEIGHT

14.06lbs

INTERPRETED BY

Maggie Machen
Lamy, DVM
DACVIM (Cardiology)

**IMAGING
PERFORMED BY**

Pamela Harrigan,
RDCS

HOSPITAL NAME

Mass Veterinary
Services

REFERRING VET

Dr. Masloski

INVOICE

25536

DATE

7/26/22